



# The Intersection Between Cerebellar Ataxia and Neuropathy: a Proposed Classification and a Diagnostic Approach

Cristina Saade Jaques<sup>1</sup> · Marcio Luiz Escorcio-Bezerra<sup>1</sup> · José Luiz Pedroso<sup>1</sup> · Orlando Graziani Povoas Barsottini<sup>1</sup>

Accepted: 2 May 2021

© The Author(s), under exclusive licence to Springer Science+Business Media, LLC, part of Springer Nature 2021

## Abstract

Neuropathy is a common associated feature of different types of genetic or sporadic cerebellar ataxias. The pattern of peripheral nerve involvement and its associated clinical features can be an invaluable aspect for narrowing the etiologic diagnosis in the investigation of cerebellar ataxias. In this review, we discuss the differential diagnosis of the intersection between peripheral nerve and cerebellar involvement, and classify them in accordance with the predominant features. Genetics, clinical features, neuroimaging, and neurophysiologic characteristics are discussed. Furthermore, a diagnostic approach for cerebellar ataxia with neuropathy is proposed according to the different clinical characteristics. This is an Educational and Descriptive review with the aim of medical education for the approach to the patients with cerebellar ataxia and neuropathy. The diagnostic approach to the patient with cerebellar ataxia with neuropathy requires a detailed medical history, phenotyping, characterization of disease progression and family history. Neuroimaging features and the neurophysiological findings play pivotal roles in defining the diagnosis. Establishing an organized classification method for the disorders based on the clinical features may be very helpful, and could be divided as those with predominant cerebellar features, predominant neuropathic feature, or conditions with both cerebellar ataxia and neuropathy. Second, determining the mode of inheritance is critical on cerebellar ataxias: autosomal dominant and recessive cerebellar ataxias, mitochondrial or sporadic types. Third, one must carefully assess neurophysiologic findings in order to better characterize the predominant pattern of involvement: damage location, mechanism of lesion (axonal or demyelinating), motor, sensory or sensory motor compromise, large or small fibers, and autonomic system abnormalities.

**Keywords** Ataxia · Peripheral neuropathy · Neurophysiology

## Introduction

Cerebellar ataxia is a syndromic diagnosis characterized by a group of specific signs and symptoms, such as unsteadiness, incoordination, gait ataxia, nystagmus, dysarthria, and dysmetria. The syndrome is caused by a multitude of neurological conditions and depending on the etiology of the cerebellar ataxia a range of associated extracerebellar manifestations may be present, like pyramidal syndrome and movement disorders, among others. Peripheral nerve damage is frequently found associated with cerebellar ataxias. In

fact, the evaluation of the pattern and clinical characteristics of the peripheral neuropathy may be invaluable in guiding the appropriate investigation of the cerebellar ataxia.

The reason for the association of these two conditions varies according to the causative factor. On some occasions the same processes that cause cerebellar atrophy will usually lead to the peripheral nerve damage. Some clinical features of the peripheral nerve involvement are helpful in defining the etiology of the cerebellar ataxia. Among those, we could highlight (1) the neurophysiologic characterization of the nerve involvement, as either axonal or demyelinating; (2) and the distribution pattern of the neuropathy, either length-dependent or diffuse as in a neuronopathy.

The neurophysiologic evaluation, through nerve conduction studies and electromyography, discloses the primary type of nerve damage, whether axonal or demyelinating. Axonal nerve damage is the most common pattern associated with cerebellar ataxias. In degenerative causes, such as

✉ José Luiz Pedroso  
zeluizpedroso@yahoo.com.br

<sup>1</sup> Department of Neurology and Neurosurgery, Escola Paulista de Medicina, Federal University of São Paulo (UNIFESP), Pedro de Toledo Street, São Paulo, SP 650, 04023-900, Brazil

Friedreich ataxia and the Spinocerebellar ataxias (SCAs), the abnormal protein deposition will cause neural damage in central and peripheral cells [1]. The mitochondrial diseases also mostly cause axonal damage to the peripheral nerves. Demyelinating neuropathy in patients with a cerebellar ataxia is particularly uncommon. Very few disorders such as Refsum disease and eventually specific subtypes of Charcot-Marie-Tooth (CMT) patients, like CMT type 4C could lead to a marked peripheral demyelination, with severely reduced conduction velocities [2].

In conditions with mixed nerve conduction abnormalities, nerve conduction abnormalities may fall either in the axonal or in the demyelinating range in the different individuals, usually with mildly abnormal or borderline values. This is usually found in cerebrotendinous xanthomatosis, autosomal recessive spastic ataxia of Charlevoix-Saguenay (ARSACS), and less frequently in degenerative disorders like the SCA3 and mitochondrial disorders.

The distribution of peripheral nerve damage most commonly present in the cerebellar ataxias is that of a length-dependent polyneuropathy, where the axons are supposedly the primary site of involvement. There are, however, some causes that lead to a sensory and/or motor neuropathy, involving mainly the cell body. Sensory or sensorimotor neuropathies are found in degenerative causes of cerebellar diseases such as SCA3 and SCA2, where there is widespread protein deposition that leads to degeneration, including central pathways and the cell body of peripheral nerves. On the other hand, autoimmune and idiopathic sensory neuropathies are sometimes associated with cerebellar atrophy [3]. In these cases, despite the evidence of a defective proprioceptive input, there is also prominent appendicular ataxia, dysarthria, and nystagmus, indicating a specific cerebellar involvement.

In order to discriminate the different patterns of peripheral nerve involvement, both clinical evaluation and complementary exams are critical tools. In sensory ataxia, besides the gait ataxia, there will be also signs of large fiber sensory involvement, such as loss of vibration and positional senses, Romberg sign, and impaired osteotendinous reflexes. Cerebellar ataxia, on the other hand, will have a wide-based ataxic gait accompanied by nystagmus, dysarthria, and appendicular incoordination.

A distal peripheral involvement may be differentiated from neuropathy through both clinical and neurophysiologic findings. In the distal nerve involvement, the sensory loss usually will be more prominent in distal lower limbs and gradually progress proximally. Neuropathies, in contrast, will have sensory and motor loss starting in upper limbs (eventually in the bulbar region), followed by a diffuse spread of the deficits. The neurophysiologic evaluation will disclose diffuse denervation in motor

neuropathies, in some cases starting by the bulbar segments. Sensory neuropathies will often display sensory nerve action potentials (SNAP) more pronouncedly reduced in upper limbs (eventually asymmetric in one body-half) and, as disease progresses, a more diffuse sensory involvement ensues. Besides, the neurophysiological blink reflex may be useful as it is typically abnormal in sensory neuropathies.

Complementary imaging studies, such as MRI, may also display specific patterns that help identify different etiologies of cerebellar involvement that may involve part of the cerebellum, like the vermis or dentate nucleus. For the characterization of the peripheral nerve involvement, MRI is also a useful tool. Sensory neuropathies may present a posterior column involvement on the MRI (spinal cord diffusion tensor imaging). Also, hereditary demyelinating neuropathies are often accompanied by nerve hypertrophy that can be characterized by nerve root and plexus imaging.

Based on the most relevant conditions where the peripheral nerve damage and the cerebellar involvement intersects, we highlight below the possible differential diagnosis, and classify them in accordance with the predominant features. Genetics, clinical features, neuroimaging, and neurophysiologic characteristics are also discussed in order to guide the diagnostic approach.

## Methods

A literature search was conducted through MEDLINE and LILACS databases using “cerebellar ataxia,” “peripheral neuropathy,” “neurophysiology,” and specific disease types (derived from the initial search) as search terms identifying hereditary/neurodegenerative and sporadic or secondary etiologies.

The search strategy was broadened to include screening of reference lists of systematic review articles for additional studies initially missed or presented only in abstract, and also include original articles, reviews or case reports, Online Mendelian Inheritance in Man, and Gene Reviews databases. No restrictions were predetermined on the year of the study. Only studies in English were included.

Only cases with molecular confirmed diagnosis were analyzed among the hereditodegenerative forms, ranging from robust samples to case reports and case series. These articles were evaluated from a clinical perspective to determine if the disorders in fact presented with the combination of both ataxia and neuropathy as contributors to the phenotype. Identified disorders were classified in the categories listed in the results.

Considering the selected articles, we have proposed a didactic classification shown in Table 1 and a diagnostic

**Table 1** Proposed classification to the different causes of diseases approaching the intersection between cerebellar ataxia and peripheral neuropathy findings

The cerebellar- neuropathy intersection	
Diseases with cerebellar involvement as main feature and associated neuropathy	
Spinocerebellar ataxias (AD)	
SCA3	
SCA2	
Other SCAs (SCA1, 6 and 7)	
AR ataxias	
Friedreich ataxia	
ARSACS	
AOA, AT, AT- like	
Multiple system atrophy	
Conditions in which the cerebellar involvement and neuropathy are equally significant features	
Genetic	
CANVAS	
Refsum	
CTX	
Mitochondrial ataxias	
MELAS	
MERRF	
NARP	
POLG disorders	
Acquired	
Alcoholic cerebellar degeneration	
Vitamin deficiency	
Toxic reaction	
Diseases with neuropathy as main feature and associated cerebellar involvement (less frequently)	
Immune-mediated sensory neuronopathy	
CMT4C	
CMTX4 (Cowchook syndrome)	

*AD*, autosomal dominant; *AOA*, ataxia with oculomotor apraxia; *AR*, autosomal recessive; *ARSACS*, autosomal recessive spastic ataxia of Charlevoix Saguenay; *AT*, ataxia telangiectasia; *CANVAS*, cerebellar ataxia, neuropathy and vestibular areflexia syndrome; *CMT*, Charcot-Marie-Tooth; *CTX*, cerebrotendinous xanthomatosis; *MELAS*, mitochondrial encephalopathy, lactic acidosis and stroke like episodes; *MERRF*, myoclonic epilepsy with ragged red fibers; *NARP*, neuropathy, ataxia and retinitis pigmentosa; *POLG*, DNA polymerase gamma (POLG) gene disorders; *SCA*, spinocerebellar ataxia

approach for the cerebellar ataxias with neuropathy based on predominant clinical features, course, brain imaging, genetics, and neurophysiology characteristics. The division proposed in Table 1 was partially based on the in the predominant clinical presentation, whether main cerebellar or predominant neuropathic involvement.

## Results

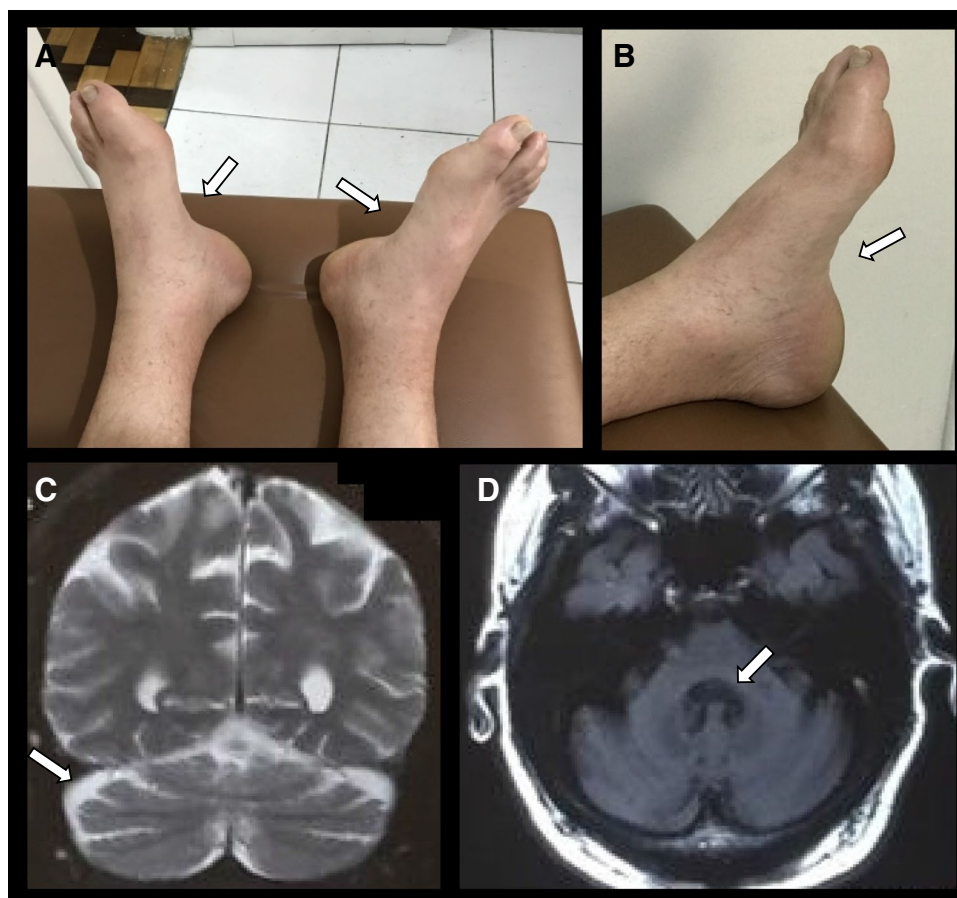
The findings of the literature review are discussed in detail. We first discourse about cerebellar ataxias presenting with neuropathy following inheritance pattern categories: autosomal dominant, autosomal recessive, mitochondrial, and

sporadic ataxias. In parallel, we present the main neurophysiology predominant findings: distribution pattern, pathology mechanism (axonal or demyelinating), motor, sensory or sensory motor compromise, large or small fibers, and autonomic system abnormalities. Figure 1 illustrates findings of cerebellar ataxia and peripheral neuropathy.

The classification is organized based on predominant feature: main cerebellar features, main neuropathic features, or both cerebellar and neuropathy findings as significant features as in Table 1. The detailed features of each of the most frequent causes are described in Table 2.

Thus, the classification was firstly based on the predominant clinical presentation, whether mostly cerebellar or neuropathic. Also, data obtained by the medical

**Fig. 1** Patient with SCA3 and pes cavus. Pes cavus is a common finding when neuropathic damage is present (A, B). Brain MRI shows global diffuse atrophy, more marked on middle and superior cerebellar peduncles, as on cerebellum (C, D). Cerebellar atrophy is easier to observe when there is advanced or pronounced cerebellum impairment



history such as a possible inheritance pattern or information indicating exposure to certain substances were also useful in the classification as proposed in Table 1. Complementary exams, specially the neurophysiologic evaluation, were able to further separate groups of disorders (as in Fig. 2) according to the pattern of peripheral nerve involvement, the type of nerve fibers involved, and the type of predominant nerve damage (either axonal or demyelinating).

## Diseases with Cerebellar Involvement as Main Feature and Associated Neuropathy

### Spinocerebellar Ataxias (Autosomal Dominant)—SCAs

**Spinocerebellar Ataxia Type 3** SCA3 is the most prevalent autosomal dominant ataxia worldwide and is caused by an unstable CAG trinucleotide repeat expansion in the *ataxin-3* gene (*ATXN3*). It can be expressed as a cerebellar ataxia associated with other symptoms in a heterogeneous manner even within the same family. Patients can be categorized

into different phenotypes according to age of onset, clinical course, and predominant features [4].

Earlier onset disease, around the second decade of life, is typically associated with severe clinical courses, extrapyramidal and pyramidal signs. Intermediate age of onset—third decade of life—the most common presentation type, is associated with pyramidal deficits and progressive external ophthalmoplegia. The later onset disease, around the fourth decade of life, is often less severe and relates to pronounced peripheral signs. Other less common symptoms includes parkinsonism, spastic paraparesis, amyotrophic lateral sclerosis (ALS)-like, or a mixed type of previously described symptoms [4, 5].

Reinnervation and ongoing denervation in multiple body regions including bulbar, cervical, thoracic, and lumbosacral regions have been reported, resembling motor neuron disease (MND) and meeting the neurophysiologic aspects of the Awaji criteria for ALS [6]. The sensory abnormalities are also, in most cases, that of a sensory neuronopathy [7]. These findings of neuropathy indicate that the main damage is probably in the cell body, either dorsal ganglion or anterior horn. Indeed, transactivation-responsive DNA-binding protein 43 (TDP-43) was reported to accumulate in the lower motor neurons, brainstem, and spinal cord in

**Table 2** Detailed clinical characteristics, brain MRI and neurophysiology findings of the diseases that compose the intersection between cerebellar ataxia and peripheral neuropathy findings

Etiology	General features	Age of onset (years)	Clinical presentation	Peripheral nerve involvement		Other electro-physiological findings	MRI	Notes
				Fiber type	Pathology			
Spinocerebellar ataxia type 3 (Machado-Joseph disease)	Most common SCA world-wide AD CAG expansion ATXN3 gene	Variable (30–50)	CA, external ophthalmoplegia, “bulging eyes”, pyramidal and extrapyramidal signs	Mostly sensorimotor Specially in subtype 3 Less severe than in SCA2 and FA	Axonal	Facial fasciculations, myokymias, continuous motor activity, MND-like Abnormal autonomic tests: cardiovascular and postganglionic sudomotor dysfunction	Atrophy of spinocerebellar tracts, pontine nuclei and dentate nuclei	
Spinocerebellar ataxia type 2	AD CAG ATXN2 gene	30–40	Progressive CA, slow saccadic eye movements, ophthalmosparesis, pyramidal, or extrapyramidal signs	Marked sensorimotor or motor	Axonal	Rarely MND-like Abnormal autonomic tests: sudomotor dysfunction	Atrophy of inferior olives, pontine nuclei and cerebellar cortex (olivoponto-cerebellar atrophy)	
Friedreich ataxia (FA)	AR GAA expansion <i>Frxataxin</i> gene	Juvenile onset	CA, neuropathy, pyramidal involvement, hypertrophic cardiomyopathy and scoliosis Clinical picture resembles CMT disease	Sensorimotor Sensory > motor	Axonal	Motor nerve conduction velocities may be close to lower limit of normality Abnormal autonomic tests: postganglionic sudomotor dysfunction	Cerebellar and cervical cord thinning	
ARSACS	AR SACS gene	Young adults (1st decade)	CA, spasticity and neuropathy	Sensorimotor	Axonal or demyelinating	Nerve conduction velocities may range from 31 to 44 m/s in UL and 20 to 40 m/s in LL. This intermediate range of velocities are within the CMT range	Cerebellar and biparietal atrophy/linear hypointensities transverse pontines	OCT: Peripapillary thickening/ macular microcysts/appearance indentation of the internal retina/ papillomacular folding

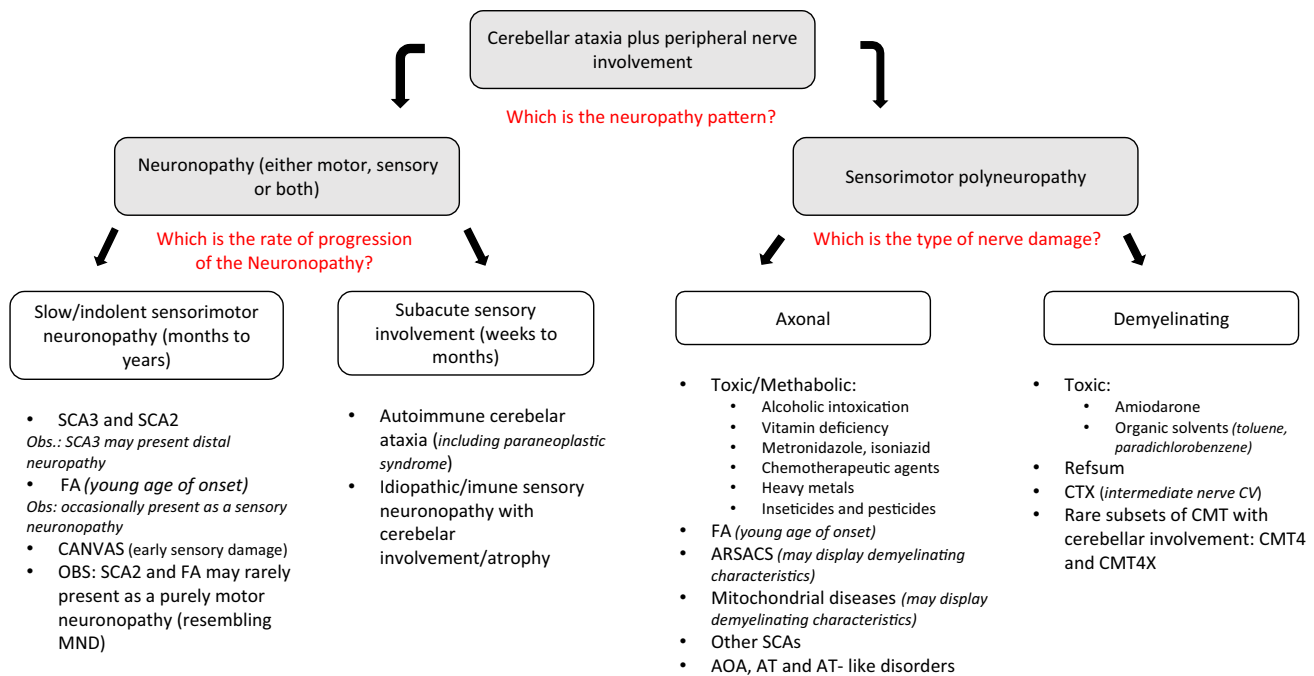
Table 2 (continued)

Etiology	General features	Age of onset (years)	Clinical presentation	Peripheral nerve involvement		Other electrophysiological findings	MRI	Notes
				Fiber type	Pathology			
AOA, AT, and AT-like disorders	AR <i>APTX</i> , <i>SEXT</i> , <i>PIK3R5</i> , <i>PNKP</i> , <i>ATM</i> , and <i>MRE11</i> genes	Childhood	CA, oculomotor apraxia, dys-tonia, mental retardation, oculocutaneous telangiectasias	Sensorimotor	Axonal	Distal polyneuropathy	Diffuse cerebellar atrophy	Cholesterol, albumin, alpha-fetoprotein and immunoglobulin changes
CANVAS	AR Intronic expansion <i>RFC1</i> gene	Adulthood	Ataxia (cerebellar and sensory components), hearing impairment, central oculomotor abnormalities	Early sensory in almost all individuals	Axonal	Diffuse neuropathy	Root ganglion, posterior columns and cerebellar atrophy (late finding)	Typical neuropathy pattern: diffusely affected SNAPs (in UL and LL). Abnormal neurophysiological blink reflex Abnormal autonomic tests
Cerebrotendinous xanthomatosis	AR <i>CYP27A1</i> gene	Infancy and late childhood	Chronic diarrhea from infancy, cataracts, psychomotor retardation, CA, myelopathy Tendinous xanthomas (highly suggestive/may not be visible)	Sensorimotor	Axonal or demyelinating (intermediate ranges of velocity)	Distal polyneuropathy	Bilateral lesions in the dentate nucleus of the cerebellum and cerebellar white matter hyperintensities	MRI or ultrasound: tendinous xanthomas
Refsum disease	AR <i>PHYH</i> gene (phytanoyl-CoA hydroxylase deficiency)	Childhood to adulthood	Retinitis pigmentosa, anosmia. Mild to severe ataxia and imbalance (mostly sensory but also CA). Ichthyosis less frequently	Sensorimotor May be initially episodic with sudden worsening	Demyelinating (non-uniform slowness of the conduction velocities)	Distal polyneuropathy	Cerebellum hyperintensities, periventricular lesions	Elevated serum phytanic acid concentration MRI and US: marked hypertrophic polyneuropathy (onion-bulb formations)

Table 2 (continued)

Etiology	General features	Age of onset (years)	Clinical presentation	Peripheral nerve involvement		Other electro-physiological findings	MRI	Notes
				Fiber type	Pathology			
Mitochondrial diseases	Mutations in the nuclear or mitochondrial DNA	Variable	Deafness, spastic paraparesis, myoclonus, myopathy, ophthalmoplegia, cognitive impairment, CA	More frequently sensorimotor	Axonal or demyelinating (intermediate ranges of velocity)	CTS and small fibers abnormalities in MELAS	White matter abnormalities and cerebellar atrophy	Plasma lactate, lactate/pyruvate ratio and muscle biopsy main be useful in selected cases
Autoimmune cerebellar ataxia and sensory neuropathy	Subacute onset (in months)	Adulthood	Sensory ataxia Pain and dysautonomia (small fiber dysfunction), CA may occur	Sensory (absent sensory potentials in the upper and lower extremities)	Axonal	Abnormal neurophysiologic blink reflex Abnormal autonomic tests	Cerebellar atrophy in part of the cases	A subgroup of patients: specific FGFR3 antibody Response to treatment varies
Alcoholic cerebellar degeneration	Indolent	Adulthood Onset and gravity depend on exposure frequency and intensity	CA (particularly lower limbs incoordination), superimposed distal loss of all sensory modalities, mild distal motor loss	Sensorimotor	Axonal	Compression neuropathies are common. Abnormal autonomic tests	Cerebellar atrophy (especially of the superior cerebellar vermis)	
Thiamine deficiency	Subacute onset (weeks to months) or slowly progressive	Adulthood Association with alcoholic degeneration	Ophthalmoplegia, nystagmus and ataxic gait There may be cardiac involvement (beriberi)	Sensorimotor	Axonal	Distal polyneuropathy	Symmetric signal abnormalities in the talami, mamillary bodies and periaqueductal area	Ophthalmoplegia and nystagmus: rapid response to thiamine reposition

AD, autosomal dominant; AOA, ataxia with oculomotor apraxia; AR, autosomal recessive; ARSACS, autosomal recessive spastic ataxia of Charlevoix Saguenay; AT, ataxia telangiectasia; CA, cerebellar ataxia; CANNVAS, cerebellar ataxia, neuropathy and vestibular areflexia syndrome; CMT, Charcot-Marie-Tooth; CTS, carpal tunnel syndrome; FA, Friedreich ataxia; LL, lower limbs; MELAS, mitochondrial encephalopathy, lactic acidosis and stroke like episodes; MND, motor neuron disease; MRI, magnetic resonance image; OCT, optic coherence tomography; SCA, spinocerebellar ataxia; SNAP, sensory nerve action potential; US, ultrasound; UL, upper limbs



**Fig. 2** Proposed algorithm approach to the diseases that compound intersection between cerebellar ataxia and peripheral neuropathy findings

SCA3 [8]. In part of the cases, however, there is a predominantly distal axonal sensorimotor polyneuropathy and eventually there is a moderate slowing of the nerve conduction velocities [9].

Data suggest that the degree of peripheral damage in SCA3/MJD seems to be related to the time period over which the *ATXN3* mutation exerts its effect, since the age-related decline of CMAP and SNAP amplitudes in SCA3 is greater than in normal subjects. However, this decline was not correlated with the CAG repeat length, age of onset, or disease duration [10].

Parasympathetic vagal fibers and postganglionic sympathetic sudomotor fibers can also be affected. Neurophysiologic evaluation usually discloses cardiac autonomic neuropathy and quantitative sudomotor axonal reflex test abnormalities [11].

**Spinocerebellar Ataxia Type 2** SCA2 is the second most prevalent autosomal dominant ataxia worldwide and it is also caused by a CAG polyglutamine expansion, which affects *ataxin-2* gene (*ATXN2*). It is characterized by cerebellar ataxia, severe saccade slowing, myoclonus, peripheral neuropathy, and MND phenotype.

Sensory and motor neuropathy are present in most of the cases, usually more pronounced than in SCA3 individuals [9, 12, 13]. Eventually there are signs of ongoing diffuse denervation, resembling MND [12]. Neurophysiologic abnormalities may precede the cerebellar syndrome [14]. Indeed, *ataxin-2* intermediate-length expansion (27–33

glutamines) was demonstrated as a relatively common ALS susceptibility gene [15].

Correlation between the neuropathy and age, disease duration, or ataxia severity is controversial [9, 12, 16]. There is no significant correlation with CAG repeat length [9]. Autonomic neurophysiologic evaluation usually unveil urinary, gastrointestinal, and sweat dysfunction, while cardiac neuropathy abnormality is controversial [17].

**Other Spinocerebellar Ataxias** SCA1 manifests with pyramidal tract signs, pale discs, and dysphagia, besides cerebellar ataxia. Nerve conduction velocities are generally more prolonged than in other SCAs [9]. Neuronopathy is the main mechanism of peripheral nerve lesion [12].

SCA6 is a late-onset pure cerebellar syndrome. Extra cerebellar signs are mild and infrequent, and include mild axonal neuropathy [9, 12]. SCA7 is a cerebellar ataxia associated with spasticity, visual impairment due to macular degeneration, and peripheral nerve involvement as consequence of neuronopathy or axonopathy [12].

## Autosomal Recessive Ataxias

**Friedreich Ataxia** Friedreich ataxia (FRDA) is the most common inherited ataxia and it is caused by a homozygous intronic GAA triplet expansion on *frataxin* (*FXN*) gene. It manifests as a juvenile onset cerebellar syndrome in association with a prominent peripheral neuropathy, which may be

associated to pes cavus. There may be associated scoliosis, subtle cognitive deficits, left ventricular concentric hypertrophy, diabetes mellitus, spasticity, urinary abnormalities, and obstructive sleep apnea in advanced stages [1].

Late-onset FRDA presents after 25 years of age and very late-onset FRDA initiates symptoms after 40 years of age. Both have mild manifestations, less extra neurological complications, and commonly present with spasticity and retained reflexes [1].

Neurophysiologic evaluation usually shows an axonal sensory distal neuropathy, characterized by markedly reduced SNAPs in lower limbs. Motor nerve involvement is less prominent [18]. These findings have no relation to the severity or duration of cerebellar ataxia since neuropathy seems to remain stable from an early stage of the disease [19]. Severe involvement and degeneration of the dorsal root ganglia, and progressive damage of dorsal columns in the spinal cord, spinocerebellar tracts, and corticospinal pathways are marked in FRDA and better explain the progressive course of the disease [20].

Autonomic nervous system alterations in FRDA apparently correlate with ataxia severity and progression rate [21]. Sweat dysfunction due to cholinergic post ganglionic fibers lesion is frequent and may even behave as a biomarker of FRDA [22].

**Autosomal Recessive Spastic Ataxia of Charlevoix-Saguenay** ARSACS predominantly starts in the first decade of life and as suggested by the acronym, its core clinical features are spasticity, ataxia, and peripheral neuropathy. Patients may have thickening peripapillary retinal nerve fiber layer on optical coherence tomography, macular microcysts, inner retina dentate appearance, and papillomacular folds. Magnetic resonance imaging (MRI) discloses cerebellar atrophy, biparietal atrophy, and the classic sign of linear pontine transverse hypointensities. Autonomic features comprise erectile dysfunction, urinary urgency, and incontinence [23, 24].

Nerve conduction studies show motor and sensory peripheral nerve involvement. Motor nerve conduction velocities are within the intermediate range of velocity reductions, between demyelinating and axonal nerve involvement. Therefore, ARSACS is a differential diagnosis with hereditary sensorimotor neuropathy syndromes, such as CMT disease [24]. Demyelinating nerve involvement is much more frequent in ARSACS than in the others recessive inherited ataxias [24].

**Ataxia with Oculomotor apraxia, Ataxia Telangiectasia, and AT-like Disorders** Ataxia with oculomotor apraxia (AOA) comprises another heterogeneous entity that can be subdivided according to its genotypes: types 1, 2, 3 (extremely rare and therefore will not be discussed), and 4. Ataxia telangiectasia (AT) or AT-like disease (ATLD) can also present as AOA. These disorders manifest early in life [25].

AOA1 is associated with mutations in the *aprataxin* gene (*APTX*) and earlier onset than AOA2. In type 1, oculomotor apraxia correlates with disease severity. Laboratory shows hypercholesterolemia and hypoalbuminemia. Sensorimotor axonal neuropathy may be associated with dystonia or mental retardation [25].

AOA2 is due to loss of function mutation in the *senataxin* gene (*SETX*). It presents with elevated immunoglobulins and alpha-fetoprotein levels. Diffuse cerebellar atrophy and sensorimotor axonal neuropathy are common—at least one of them must be present at diagnosis [26]. Interestingly, *SETX* mutations are also related to dominantly inherited juvenile ALS type 4 [27].

AOA 4 results from a *polynucleotide kinase 30-phosphatase* (*PNKP*) mutation. Dystonia may be the first symptom and a pronounced large fiber polyneuropathy is the most prominent sign [28]. *PNKP* mutations are associated to a dominantly inherited infantile onset epileptic encephalopathy with microcephaly, but there are also reports of a recessive axonal CMT-like phenotype with cerebellar ataxia [29].

AT due to mutations in the *A-T mutated* (*ATM*) gene is associated with chromosomal instability, cell cycle abnormalities, immunodeficiency, lymphoreticular malignancy predisposition, and acute sensitivity to ionizing radiations. Patients may present with oculocutaneous-dilated blood vessels (telangiectasias) and elevated alpha-fetoprotein [30, 31]. Sural nerve biopsy also indicates axonal degeneration [32]. Abnormalities appear to worsen with age and disease severity [33].

Mutations in *meiotic recombination 11* (*MRE11*) were identified in ATLD patients, also with chromosomal instability and sensitivity to ionizing radiations. They may present with cerebellar atrophy and a mild axonal sensorimotor neuropathy [34].

## Multiple System Atrophy—Cerebellar Form

Multiple system atrophy (MSA) is a neurodegenerative alpha synucleinopathy that manifest primarily with progressive multidomain autonomic failure and is divided in two subtypes according to its associated predominant features: parkinsonian type (MSA-P) due to striatonigral degeneration or cerebellar variant (MSA-C) defined by olivopontocerebellar atrophy. It may also present pyramidal signs, inspiratory stridor, rapid eye movement sleep behavior disorder, bent spine, anterocollis, and hand or foot dystonia [35]. Neuropathy may be present in about 40% of these patients and is usually mild or asymptomatic, with a predominantly motor involvement and more prevalent in MSA-P. Autonomic tests show severe and widespread anhidrosis due to postganglionic sudomotor failure in some patients or preganglionic lesion in others. Vagal abnormalities are common findings on heart rate variability tests [36, 37].

## Conditions in Which the Cerebellar Involvement and Neuropathy are Equally Significant Features

### Autosomal Recessive Ataxias

**Cerebellar Ataxia with Neuropathy and Vestibular Areflexia Syndrome** CANVAS presents with the triad of symptoms that gives its name and is caused by an intronic expansion in the *replication factor C (RFC1)* gene. It is a slowly progressive adult ataxia in which there is disturbance of the three cardinal pillars of human balance: the cerebellum, vestibular, and sensory systems. Abnormal visually enhanced vestibulo-ocular reflex (VOR) is the clinical hallmark [38]. Clinical features include tinnitus, hearing impairment, chronic cough, central oculomotor abnormalities with reduced or absent VOR, and autonomic dysfunction. There is atrophy of dorsal root ganglion, posterior columns, and cerebellum that predominates in the anterior and dorsal vermis and also lateral hemispheric atrophy affecting crus I [38, 39]. Cerebellar gait ataxia and incoordination may be present early on, while cerebellar atrophy may be a very late feature [38].

Sensory neuronopathy is the most typical electrodiagnostic finding, including abnormal blink reflex (indicating a trigeminal involvement) in part of the patients. However, sensorimotor neuropathy, or a predominantly or pure small fiber neuropathy may also be present. According to the electrophysiological criteria, nerve conduction studies should include abnormal SNAP in at least one upper and one lower extremity to meet the minimum request for clinically possible CANVAS [38, 39].

**Cerebrotendinous Xanthomatosis** Cerebrotendinous xanthomatosis (CTX) is a lipid storage disease caused by mutation in the *cytochrome P450 family 27 subfamily A member 1 (CYP27A1)* gene. The affected mitochondrial enzyme is involved in cholesterol metabolism and bile acid synthesis and produces elevated levels of cholestanol and bile alcohols in serum and urine. Clinical features comprise diarrhea starting from infancy, seizures, intellectual disability, cataracts, tendon xanthomas, dystonia, dementia, and psychiatric issues. MRI discloses bilateral lesions in the dentate nucleus of the cerebellum [40]. Sensorimotor polyneuropathy is present but there are controversies about the underlying pathogenesis (either primarily axonal [41, 42] or demyelinating process [43]). Nerve conduction usually discloses velocity abnormalities in the intermediate range. There is also evidence of dysautonomia and small fiber compromise [41]. Oral chenodeoxycholic acid (CDCA) improves most symptoms and nerve conduction velocities [42].

**Refsum Disease** Refsum disease is caused by deficiency of *phytanoyl-CoA 2-hydroxylase* encoded by *PHYH* in 90% of patients or deficiency of the *peroxisomal biogenesis factor 7 (PEX7)* in fewer than 10%. Symptoms include anosmia and early-onset retinitis pigmentosa, with variable combinations of neuropathy, deafness, ataxia, short metacarpals and metatarsals, and ichthyosis. Later in life, cardiac arrhythmia and heart failure due to cardiomyopathy may develop. High levels of plasma phytanic acid and raised cerebrospinal fluid protein concentrations are characteristic. Neurophysiologic evaluation usually discloses sensorimotor demyelinating neuropathy with non-uniform nerve conduction slowing. The peripheral nerve involvement is characteristically hypertrophic, due to the frequent and repetitive demyelination and remyelination along the years. This diffuse thickening of nerves may be evidenced by MRI and nerve Ultrasonography. High-calorie diet prevents mobilization of phytanic acid into the plasma and restriction of phytanic acid intake helps resolve ichthyosis, sensory neuropathy, and ataxia [44].

### Mitochondrial Ataxias

Mitochondrial diseases constitute a heterogeneous group of disorders caused by mutations either in nuclear or in mitochondrial DNA. They manifest as systemic disorders and may present with a constellation of symptoms such as deafness, impaired glycemic control/diabetes, short stature, myoclonus, neuropathy, or spastic paraparesis. Some of them present as a pure progressive ataxia or, more commonly, as an ataxia-plus syndrome [45].

MELAS is the acronym for mitochondrial encephalopathy, lactic acidosis, and stroke like episodes, and is caused mostly by mutation in *m.3243A > G* in the *mitochondrially encoded TRNA-Leu 1 (MT-TL1)* gene. Nerve conduction studies typically show an axonal or mixed axonal and demyelinating sensorimotor neuropathy that seems to relate with higher age and male gender. There is also a higher prevalence of carpal tunnel syndrome and some evidence of small fiber compromise in these patients [46].

MERRF stands for myoclonic epilepsy with ragged red fibers and it is mostly caused by an *8344A.G mitochondrial DNA* mutation. Clinical picture is characterized by muscle weakness, ataxia, seizures, hearing loss, cognitive impairment, neuropathy, exercise intolerance and increased creatine kinase levels, among others. Neuropathy is axonal, mainly sensory or less frequently sensorimotor [47]. Neurogenic muscle weakness, ataxia, and retinitis pigmentosa (NARP) is characterized by proximal neurogenic weakness with stocking-glove sensory loss due to axonopathy, ataxia, and retinitis pigmentosa. It is caused by *mitochondrially encoded ATP Synthase Membrane subunit 6 (MT-ATP6)* mutations [48].

Mutations in the *mitochondrial DNA polymerase gamma (POLG)* gene encompass a pleomorphic spectrum of disorders which include POLG-related ataxia neuropathy spectrum (ANS). Clinical features are characterized mainly by overlapping ataxia and neuropathy. Polyneuropathy is an early feature. It is almost exclusively a sensory neuropathy with an axonal type of nerve involvement. In this group are included mitochondrial recessive ataxia syndrome (MIRAS), spinocerebellar ataxia and epilepsy (SCAE), myoclonus epilepsy myopathy sensory ataxia (MEMSA), and sensory ataxia neuropathy dysarthria and ophthalmoplegia (SANDO) [49].

## Acquired Ataxias

**Alcoholic Cerebellar Degeneration** Chronic alcohol abuse can cause damage to the central and peripheral nervous systems ranging from clinically subtle effects to severe nervous involvement, usually irreversible. These effects are most probably due to a combination of direct alcohol toxicity, nutritional deficiencies, and liver dysfunction. Cerebellar ataxia is usually associated with long-term heavy alcohol abuse. Neuroimage shows anterior–superior vermian atrophy clinically accompanied by axial ataxia [50].

Peripheral neuropathy is present in almost 90% of chronic alcohol users and is possibly the earliest neurologic complication of alcoholism, usually more severe with cumulative alcohol abuse along the years. The polyneuropathy often presents as a length-dependent sensorimotor axonopathy affecting both large myelinated and small unmyelinated fibers. Autonomic testing of parasympathetic reflexes is often abnormal [51]. Other common complications of alcoholism are compression neuropathies at different sites, such as radial lesion at the spiral groove, ulnar neuropathy at the elbow, radial or axillary nerve injury in the axilla, and fibular neuropathy at the fibular head [52].

Alcohol cessation, vitamins, and symptomatic medications are the target treatment. Recovery is incomplete if there is severe neuropathy at presentation and established cerebellar degeneration is irreversible [50].

**Vitamin Deficiency** Thiamine deficiency is frequently observed in chronic alcohol abuse, but may also be present in other clinical contexts as in hyperemesis gravidarum, acquired immunodeficiency syndrome, and malignancy. Cobalamin deficiency risk factors include reduction in intrinsic factor, which is common in elderly, gastric or terminal ileum resection, strict vegetarianism, pregnancy, and exposure to nitrous oxide [53].

Cerebellar ataxia usually appears before the cognitive features in Wernicke encephalopathy due to thiamine deficiency, often along with ophthalmoparesis [54]. Thiamine

deficiency–related axonal neuropathy can develop rapidly in a few months and lead to a severe subacute weakness and sensory ataxia, resulting in the classical beriberi clinical picture, which may be associated with cardiac dysfunction [55].

Vitamin B12 or cobalamin deficiency can result in either an axonal or demyelinating neuropathy, affecting predominantly thick nerve fibers. It often is accompanied by myelopathy (subacute combined degeneration of the spinal cord) and hematological manifestations. It may rarely cause cerebellar ataxia or optic neuropathy. MRI demonstrates spinal cord, brain (predominantly periventricular white matter), or cerebellar demyelination [53, 55].

Diagnosis is based on measurement of serum vitamin levels or substrates such as homocysteine and methylmalonic acid, and treatment consists of vitamin replacement [53, 55].

**Toxic Causes of Ataxia and Neuropathy** Several external agents can cause the combination of cerebellar ataxia and neuropathy. Among them, there are antibiotics, antineoplastics, heavy metals, and solvents that can cause intoxication from exposure in an occupational setting, clinical/therapeutic use of certain medications or recreational substance abuse. Most of them ameliorate with removal of exposure. Table 3 summarizes some examples [56, 57].

Neurotoxicity is a well-recognized feature of chemotherapeutic agents, but should be an exclusion diagnosis in those individuals with previous neoplastic lesions and new onset of central or peripheral signs/symptoms. Primarily a review of more common causes must be carried out, such as alcohol toxicity or vitamin deficiency or even rarer situations like neoplastic nerve infiltration or paraneoplastic syndromes [58].

The chemical and physical forms of heavy metals determine how human exposure occurs. There are well-defined acute or chronic clinical features that usually correspond to the duration and intensity of the exposure of some agents. Organic solvents are lipophilic, volatile, and can be involuntarily or voluntarily inhaled causing central nervous system intoxication. They are widely used at occupational settings such as chemical or plastic industries and as glue components (toluene, benzene, acetone, xylene), petrol (hydrocarbons, tetraethyl lead), lighter refills (butane), acrylic paints (toluene), aerosols (fluorocarbons), and cleaning fluids (toluene, halogenated hydrocarbons). Insecticides and pesticides are widely used in agriculture and even in low doses; they potentially cause toxic symptoms. Exposure can occur by skin contamination, inhalation or ingestion, in occupational or suicide attempt settings. Intensive support and substance removal (gastric lavage, removal of contaminated clothes, and skin wash) are the main treatment [56, 57].

**Table 3** Detailed clinical characteristics, brain MRI and neurophysiology findings of the medications and other substances whose intoxication can cause cerebellar ataxia and peripheral neuropathy

Substance classification	Substance	Exposure conditions	Clinical presentation	Peripheral nerve involvement		Other electrophysiological findings	MRI	Notes
				Fiber type	Pathology			
Antibiotic	Metronidazole	Especially: high doses, prolonged use Also at doses within and above the recommended range	CA, encephalopathy seizures	Sensory > motor	Axonal	Distal polyneuropathy	Bilateral symmetric lesions hyperintense on T2 in the supratentorial WM, dentate nucleus, midbrain tectum and corpus callosum splenium	Reverse after few weeks of discontinuation
Antiarrhythmic	Amiodarone	Duration of treatment: related with a higher prevalence of toxicity	CA, encephalopathy, rest tremor, dyskinesia, myoclonus, rarely parkinsonism/proximal myopathy Pulmonary fibrosis, thyroid abnormalities, ocular sequelae, skin discoloration, elevated hepatic enzymes	Sensorimotor	Axonal or demyelinating (mimicking CIDP if chronic use)	Distal polyneuropathy	Rarely proximal myopathy	Improves slowly with discontinuation
Tuberculosis agent	Isoniazid	Related to interruption of pathways responsible for pyridoxine phosphorylation	CA, seizures, dizziness	Sensorimotor	Axonal	Distal polyneuropathy	Symmetric hyperintensity involving bilateral dentate nuclei of the cerebellum on T2/FLAIR sequences (resembling metronidazole toxicity)	
Chemotherapeutic agents	Cytarabine or cytosine arabinoside (Ara-C)	Treatment of leukemia and lymphoma Effect is related to elevated IV doses/begins within a few days after the infusion	Severe CA, confusion, lethargy, anosmia, lateral rectus palsy, bulbar palsy, Horner syndrome, aseptic meningitis, locked in syndrome, encephalitis, extrapyramidal symptoms	Pure sensory to a Guillain-Barré-like	Axonal	Distal polyneuropathy	Normal image or cerebellar cortical atrophy with diffuse or multifocal WM T2 abnormalities	May not reverse after medication withdrawn Reversible after withdraw
	Nelarabine		CA, cognitive decline, headache, seizure, tremor, weakness	Early sensory or motor	Axonal	Distal polyneuropathy		
	Procarbazine (alkylating agent)		CA, rarely encephalopathy Hematopoietic suppression: leukopenia, thrombocytopenia		Axonal	Distal polyneuropathy		Improves after months of withdraw
	Vincristine (vinca alkaloid)	Treatment of hematologic malignancies as leukemias and lymphomas	Severe PN Less often: encephalopathy, seizures, SIADH, CA, transient cortical blindness, parkinsonism, atetosis	Sensorimotor	Axonal	Distal polyneuropathy	Cranial nerve involvement Autonomic dysfunction	

**Table 3** (continued)

Substance classification	Substance	Exposure conditions	Clinical presentation	Peripheral nerve involvement		Other electrophysiological findings	MRI	Notes
				Fiber type	Pathology			
Heavy metals	Mercury	Inhaled vapor: occupational activities as gold mining Ingested (methyl-mercury): seafood tissues	CA, gastrointestinal symptoms, impairment of hearing, constricted visual fields Renal failure, psychiatric symptoms, acrodynia Sensory symptoms: association of PN and central sensory deficit	Early subacute sensory > motor	Axonal	Distal polyneuropathy or polyradiculopathy	Atrophy of postcentral cortex, visual cortex, cerebellar vermis – inferior and middle parts—and cerebellar hemispheres	Treatment: chelation and removal of exposure
	Lead	Ingestion: paints Exposure: contaminated flour, lead stearate, alloys, rubber, pigments and automobile batteries Children are more vulnerable	Hypertension, abdominal pain and others gastrointestinal effects, anemia, psychiatric and neurological symptoms (prominent CA, cognitive deficits and PN) Classical bluish gray discoloration of the gums	Mixed motor > sensory	Axonal	Distal polyneuropathy	T2 hyperintensities in both thalami, periventricular WM, posterior thalamus, and pons Reported: severe cerebellar edema with obstructive hydrocephalus	Chelation therapy: dimercaptosuccinic acid
Organic solvents	Toluene	Ingestion: contaminated water or food Inhalation of dust Dermal/mucous absorption or by homicide attempts	Acute gastroenteritis, tachycardia, hypertension, arrhythmia (alterations on ST and T wave on ECG) Loss of consciousness, seizures, blurred vision, tremor, CA, early-onset PN Chronically: anorexia, headache, diffuse pain, infertility and white streaks (Mee's lines) on fingernails and toenails, blindness and death	Mixed motor > sensory	Axonal	Distal polyneuropathy	Especially dangerous: colorless, odorless, and tasteless Treatment: supportive measures on ICU, hemoperfusion, continuous veno-venous hemofiltration, forced diuresis, supplementation with potassium chloride Antidote: Prussian blue	
	Paradichlorobenzene	Glue-sniffing especially in teenagers and young adults Household deodorant in mothball and toilet bowl fresheners	Headache, hallucinations, cognitive decline, decreased olfaction, hearing loss and the classical features: optic atrophy, prominent global CA PN, hepatotoxicity, hemorrhagic pulmonary edema, gastrointestinal symptoms, cardiac injury, arrhythmia, rhabdomyolysis and hydro electrolytic disturbances	Sensorimotor	Demyelinating: proximal motor conduction block, prominent slowing CV	Distal polyneuropathy	Diffuse WM hyperintensity of pyramidal and pontocerebellar tracts, hypointense thalami and basal ganglia, and diffuse brain atrophy	Recover after a few months, but a permanent CA syndrome can remain

**Table 3** (continued)

Substance class-sification	Substance	Exposure conditions	Clinical presentation	Peripheral nerve involvement		MRI	Notes
				Fiber type	Pathology		
Insecticides and pesticides	Organophosphorus		Cholinergic crisis (muscarinic) followed when in higher doses by muscle fasciculation, tremor and flaccid paralysis (nicotinic) CA: within a week after the exposure/limited course PN: about a month of the exposure Seizure, opsoclonus, insomnia, nightmare, drowsiness, dystonic reactions late-onset spasticity	Motor	Axonal	Distal polyneuropathy	Atropine and oximes administration (e.g., pralidoxime): effective antidotes Benzodiazepines: seizure and anxiety treatment
	Organochlorine	Older class of insecticides	Tremor, mouth and face paresthesia, startle reactions, seizures, CA, opsoclonus, slurred speech, PN				Phenytoin, benzodiazepines, and calcium gluconate: symptomatic role
	Methyl Bromide	Gas mainly used as a soil fumigant, in chemical processes, as a refrigerant or as a component in fire extinguishers	Acute poisoning: Pan CA, seizures, myoclonus, encephalopathy, pyramidal and vestibular signs Chronic/subacute low-level poisoning: PN	Sensorimotor	Axonal	Distal polyneuropathy	Symmetrical T2/FLAIR hyperintensity: dentate nucleus of the cerebellum, periventricular area of the 4th ventricle, dorsal medulla and pons, periaqueductal GM, superior and inferior colliculi, posterior putamen, subthalamic nuclei, corpus callosum splenium

CA, cerebellar ataxia; CV, conduction velocity; ECG, electrocardiogram; GM, gray matter; ICU, intensive care unit; IV, intravenous; PN, peripheral neuropathy; PSW, positive sharp waves; SIADH, syndrome of inappropriate antidiuretic hormone secretion; WM, white matter

## Diseases with Neuropathy as Main Feature and Associated Cerebellar Involvement (Less Frequently)

### Autoimmune Ataxias with Associated Neuropathy

Autoimmune and idiopathic sensory neuronopathies are frequently not clearly differentiated. Even though no specific antibody is present in most of the cases, in the absence of other causative factor, a neuropathy is eventually considered as immune-mediated event, depending on the clinical course and response to immunotherapy. Indeed, sensory neuronopathies are frequently associated with systemic autoimmune diseases like Sjogren's syndrome, autoimmune hepatitis and celiac disease [59]. In most of the patients with an initially idiopathic sensory neuropathy in which an associated cerebellar ataxia was found, evidence of an immune defect was eventually diagnosed [60]. Paraneoplastic etiology should also be considered in the context of autoimmune cerebellar ataxia and subacute sensory neuropathy, and may be associated to autonomic changes [61].

Celiac disease is a systemic chronic immune-mediated disorder caused by innate and adaptive immune responses to gluten peptides in genetically susceptible patients. It may present with diarrhea, malabsorption features (iron-deficiency anemia, osteoporosis), dermatitis herpetiformis, and neurologic involvement characterized mainly by peripheral neuropathy and gluten ataxia. The neurologic symptoms onset is around 50 years of age and may have no associated enteropathy [62]. Neurophysiologic studies usually demonstrate sensorimotor axonal neuropathy, but there are also reports of asymmetrical neuropathy and also sensory neuropathy, which is particularly characteristic [63]. Cardiac autonomic tests may show abnormalities in parasympathetic and sympathetic function [64]. Adherence to a gluten-free diet appeared to improve both neuropathy and ataxia. Treatment response varies depending on the duration and severity of the disease [62, 63].

### Ataxia and the Charcot-Marie-Tooth-wide Phenotypic Spectrum

CMT is a clinically and genetically heterogenous group of inherited peripheral neuropathies characterized mainly by long-standing motor and/or sensory polyneuropathy in which the nerve damage may be either primarily axonal or demyelinating. In previous times, FRDA patients were frequently initially diagnosed as CMT,

which is much less probably with nowadays diagnostic resources [65]. However, late-onset axonal polyneuropathy cases, especially those with additional phenotypic features, like pyramidal signs, should be considered for *FXN* gene testing considering the LOFA cases. Besides, ARSACS patients also have been described to present with isolated sensorimotor neuropathy with mixed axonal and demyelinating findings on nerve conduction studies, eventually resembling CMT [24]. Therefore, careful clinical phenotyping usually unveils subtle cerebellar and/or pyramidal signs [24, 66].

Rarely, specific CMT subtypes may present true cerebellar ataxia. CMT type 4C (CMT4C) is a demyelinating neuropathy caused by a biallelic mutation in the *SH3 domain and tetratricopeptide repeats 2 (SH3TC2)* gene and is characterized by early onset (infancy), slowly progressive severe sensorimotor polyneuropathy. It is one of the most prevalent recessive CMT. Even though in most cases of CMT4C, the polyneuropathy is severe, recent reports showed that abnormalities in the *SH3TC2* gene may also share some features of an areflexic, hypotonic FRDA-like phenotype, including cerebellar atrophy and cerebellar ataxia [2].

X-linked recessive CMT-4 (CMTX4) is a mitochondrial disorder due to mutation in the *apoptosis inducing factor mitochondria associated 1 (AIFM1)* gene. It is characterized by highly variable features. Age of onset range from infancy to young adulthood and severity of the neurologic features are highly variable too, but most patients present with progressive sensorimotor axonal neuropathy and deafness due to auditory nerve involvement. Other features may include cognitive impairment, cerebellar atrophy, and cerebellar signs and symptoms [67].

## Conclusions

The cerebellar ataxias are a heterogenous group of disorders with a vast number of etiologies, which may be accompanied by different multisystemic involvement. Particularly, the peripheral nervous system is frequently associated with the cerebellar ataxias and should be cautiously characterized as it can provide important diagnostic clues. The peripheral nerve involvement pattern (e.g., distal polyneuropathy or neuronopathy) and the type of nerve damage (i.e., axonal or demyelinating) are important aspects to be attentive to, along with rate of progression of neuropathy. Therefore, a diagnostic approach for the cerebellar ataxias with neuropathy is proposed on Fig. 2. Besides the clinical neurologic evaluation, brain and peripheral nerve imaging, as well as neurophysiologic evaluation, are essential tools for characterizing the clinical involvement of the cerebellum and peripheral nervous system.

**Authors' Contributions** CSJ: planned, organized and executed the study. Wrote and submitted this work. (nothing to disclose). MLEB: reviewed and criticized the survey (nothing to disclose). JLP: conceived, planned and organized, reviewed and criticized the survey (Nothing to disclose). OGPB: conceived, planned and organized, reviewed and criticized the survey (nothing to disclose).

## Declarations

**Conflict of Interest** The authors declare that they have no conflict of interest.

## References

- Cook A, Giunti P. Friedreich's ataxia: clinical features, pathogenesis and management. *Br Med Bull*. 2017;124(1):19–30.
- Skott H, Muntean-Firanesco C, Samuelsson K, Verrecchia L, Svenningsson P, et al. The cerebellar phenotype of Charcot-Marie-Tooth neuropathy type 4C. *Cerebellum Ataxias*. 2019;6(1):6–12.
- Damasceno A, França MC Jr, Cendes F, Nucci A. Cerebellar atrophy is frequently associated with non-paraneoplastic sensory neuronopathy. *Arq Neuropsiquiatr*. 2011;69(4):602–6.
- Moro A, Munhoz RP, Arruda WO, Raskin S, Moscovich M, et al. Ataxia espinocerebelar do tipo 3: subfenótipos em uma coorte de pacientes brasileiros. *Arq Neuropsiquiatr*. 2014;72(9):659–62.
- Teive HAG, Munhoz RP, Arruda WO, Lopes-Cendes I, Raskin S, et al. Spinocerebellar ataxias - genotype-phenotype correlations in 104 Brazilian families. *Clinics*. 2012;67(5):443–9.
- Pinto S, De CM. Machado-Joseph disease presenting as motor neuron disease. *Amyotroph Lateral Scler*. 2008;9(3):188–91.
- Escorcio-Bezerra ML, Pedroso JL, Pinheiro DS, Braga-Neto P, Barsottini OGP, et al. Pattern of peripheral nerve involvement in machado-joseph disease: neuronopathy or distal axonopathy? A clinical and neurophysiological evaluation. *Eur Neurol*. 2013;69(3):129–33.
- Tan CF, Yamada M, Toyoshima Y, Yokoseki A, Miki Y, et al. Selective occurrence of TDP-43-immunoreactive inclusions in the lower motor neurons in Machado - Joseph disease. *Acta Neuropathol*. 2009;118(4):553–60.
- Linnemann C, Du MST, Rakowicz M, Schmitz-Hübsch T, Szymanski S, et al. Peripheral neuropathy in spinocerebellar ataxia type 1, 2, 3, and 6. *Cerebellum*. 2016;15(2):165–73.
- Klockgether T, Schöls L, Abele M, Bürk K, Topka H, et al. Age related axonal neuropathy in spinocerebellar ataxia type 3/ Machado-Joseph disease (SCA3/MJD). *J Neurol Neurosurg Psychiatry*. 1999;66(2):222–4.
- Takazaki KAG, D'Abreu A, Nucci A, Lopes-Cendes I, França MC. Dysautonomia is frequent in Machado-Joseph disease: clinical and neurophysiological evaluation. *Cerebellum*. 2013;12(4):513–9.
- Van De WBPC, Notermans NC, Schelhaas HJ, Van AN, Sinke RJ, et al. Peripheral nerve involvement in spinocerebellar ataxias. *Arch Neurol*. 2004;61(2):257–61.
- Bezerra MLE, Pedroso JL, Braga-Neto P, Abrahao A, de Albuquerque MVC, et al. Pattern of peripheral nerve involvement in spinocerebellar ataxia type 2: a neurophysiological assessment. *Cerebellum*. 2016;15(6):767–73.
- Pérez LV, Cruz GS, Ochoa NC, Labrada RR, Díaz JR, et al. Electrophysiological features in patients and presymptomatic relatives with spinocerebellar ataxia type 2. *J Neurol Sci*. 2007;263(1–2):158–64.
- Elden AC, Kim H, Hart MP, Chen-plotkin AS, Johnson S, et al. Ataxin-2 intermediate-length polyglutamine expansions are associated with increased risk for ALS. *Nature*. 2010;466(7310):1069–75.
- Pelosi L, Iodice R, Antenora A, Kilfoyle D, Mulroy E, et al. Spinocerebellar ataxia type 2—neuronopathy or neuropathy? *Muscle Nerve*. 2019;60(3):271–8.
- Indelicato E, Fanciulli A, Ndayisaba JP, Nachbauer W, Granata R, et al. Autonomic function testing in spinocerebellar ataxia type 2. *Clin Auton Res*. 2018;28(3):341–6.
- Caruso G, Santoro L, Perretti A, Serlenga L, Crisci C, et al. Friedreich's ataxia: electrophysiological and histological findings. *Acta Neurol Scand*. 1983;67(1):26–40.
- Santoro L, Perretti A, Crisci C, Ragno M, Massini R, et al. Electrophysiological and histological follow-up study in 15 Friedreich's ataxia patients. *Muscle Nerve*. 1990;13(6):536–40.
- Zouari M, Feki M, Ben Hamida C, Larnaout A, Turki I, et al. Electrophysiology and nerve biopsy: comparative study in Friedreich's ataxia and Friedreich's ataxia phenotype with vitamin E deficiency. *Neuromuscul Disord*. 1998;8(6):416–25.
- Indelicato E, Fanciulli A, Ndayisaba JP, Nachbauer W, Eigentler A, et al. Autonomic function testing in Friedreich's ataxia. *J Neurol*. 2018;265(9):2015–22.
- Takazaki KAG, Rezende TJR, Martinez ARM, Gonzalez-Salazar C, Nucci A, et al. Sandomotor dysfunction is frequent and correlates with disability in Friedreich ataxia. *Clin Neurophysiol*. 2018;129(11):2290–5.
- Rezende Filho FM, Parkinson MH, Pedroso JL, Poh R, Faber I, et al. Clinical, ophthalmological, imaging and genetic features in Brazilian patients with ARSACS. *Park Relat Disord*. 2018;2019(62):148–55.
- Vill K, Müller-Felber W, Gläser D, Kuhn M, Teusch V, et al. SACS variants are a relevant cause of autosomal recessive hereditary motor and sensory neuropathy. *Hum Genet*. 2018;137(11–12):911–9.
- Bohlega SA, Shinwari JM, Al Sharif LJ, Khalil DS, Alkhairallah TS, et al. Clinical and molecular characterization of ataxia with oculomotor apraxia patients in Saudi Arabia. *BMC Med Genet*. 2011;12:1–7.
- Anheim M, Monga B, Fleury M, Charles P, Barbot C, et al. Ataxia with oculomotor apraxia type 2: clinical, biological and genotype/phenotype correlation study of a cohort of 90 patients. *Brain*. 2009;132(10):2688–98.
- Bassuk AG, Chen YZ, Batish SD, Nagan N, Opal P, et al. In cis autosomal dominant mutation of Senataxin associated with tremor/ataxia syndrome. *Neurogenetics*. 2007;8(1):45–9.
- Bras J, Alonso I, Barbot C, Costa MM, Darwent L, et al. Mutations in PNKP cause recessive ataxia with oculomotor apraxia type 4. *Am J Hum Genet*. 2015;96(3):474–9.
- Pedroso JL, Rocha CRR, Macedo-Souza LI, De MV, Marques W, et al. Mutation in PNKP presenting initially as axonal Charcot-Marie-Tooth disease. *Neurol Genet*. 2015;1(4):e30.
- Savitsky K, Bar-Shira A, Gilad S, Rotman G, Ziv Y, et al. A single ataxia telangiectasia gene with a product similar to PI-3 kinase. *Science*. 1995;268(5218):1749–53.
- Dunn HG. Nerve conduction studies in children with Friedreich's ataxia and ataxia-telangiectasia. *Dev Med Child Neurol*. 1973;15(3):324–37.
- Barbieri F, Santoro L, Crisci C, Massini R, Russo E, et al. Is the sensory neuropathy in ataxia-telangiectasia distinguishable from that in Friedreich's ataxia? *Acta Neuropathol*. 1986;69(3–4):213–9.
- Taylor MJ, Chan-Lui WY, Logan WJ. Longitudinal evoked potential studies in hereditary ataxias. *Can J Neurol Sci*. 1985;12(2):100–5.
- Delia D, Paine M, Buscemi G, Savio C, Palmeri S, Lulli P, et al. MRE11 mutations and impaired ATM-dependent responses in

- an Italian family with ataxia-telangiectasia-like disorder. *Hum Mol Genet.* 2004;13(18):2155–63.
35. Fanciulli A, Wenning GK. Multiple-system atrophy. *N Engl J Med.* 2015;372(3):249–63.
  36. Kuzdas-Wood D, Irschick R, Theurl M, Malsch P, Mair N, et al. Involvement of peripheral nerves in the transgenic PLP- $\alpha$ -syn model of multiple system atrophy: extending the phenotype. *PLoS ONE.* 2015;10(10):1–17.
  37. Rodolico C, Toscano A, De LG, Mazzeo A, Di LR, et al. Peripheral neuropathy as the presenting feature of multiple system atrophy. *Clin Auton Res.* 2001;11(2):119–21.
  38. Szmulewicz DJ, Roberts L, McLean CA, MacDougall HG, Michael Halmagyi G, et al. Proposed diagnostic criteria for cerebellar ataxia with neuropathy and vestibular areflexia syndrome (CANVAS). *Neurol Clin Pract.* 2016;6(1):61–8.
  39. Cortese A, Simone R, Sullivan R, Vandrovцова J, Yau WY, et al. Biallelic expansion of an intronic repeat in RFC1 is a common cause of late-onset ataxia. *Nat Genet.* 2019;51(4):649–58.
  40. Raymond GV, Schiffmann R. Cerebrotendinous xanthomatosis: the rare “treatable” disease you never consider. *Neurology.* 2019;92(2):61–2.
  41. Chen SF, Tsai NW, Chang CC, Lu CH, Huang CR, et al. Neuromuscular abnormality and autonomic dysfunction in patients with cerebrotendinous xanthomatosis. *BMC Neurol.* 2011;11:63.
  42. Ginanneschi F, Mignarri A, Mondelli M, Gallus GN, Del PM, et al. Polyneuropathy in cerebrotendinous xanthomatosis and response to treatment with chenodeoxycholic acid. *J Neurol.* 2013;260(1):268–74.
  43. Pilo B, De BG, Sobrido MJ, Navarro C, Grandas F, et al. Neurophysiological study in cerebrotendinous xanthomatosis. *Muscle Nerve.* 2011;43(4):531–6.
  44. Wanders RJA, Waterham HR, Leroy BP. Refsum Disease. 2006 Mar 20 [updated 2015 Jun 11]. In: Adam MP, Ardinger HH, Pagon RA, Wallace SE, Bean LJH, et al, editors. *GeneReviews*® [Internet]. Seattle (WA): University of Washington, Seattle; 1993–2021.
  45. Bargiela D, Shanmugarajah P, Lo C, Blakely EL, Taylor RW, et al. Mitochondrial pathology in progressive cerebellar ataxia. *Cerebellum Ataxias.* 2015;2(1):1–5.
  46. Kaufmann P, Pascual JM, Anziska Y, Gooch CL, Engelstad K, et al. Nerve conduction abnormalities in patients with MELAS and the A3243G mutation. *Arch Neurol.* 2006;63(5):746–8.
  47. Mancuso M, Orsucci D, Angelini C, Bertini E, Carelli V, et al. Phenotypic heterogeneity of the 8344A>G mtDNA “MERRF” mutation. *Neurology.* 2013;80(22):2049–54.
  48. Thorburn DR, Rahman J, Rahman S. Mitochondrial DNA-Associated Leigh Syndrome and NARP. 2003 Oct 30 [updated 2017 Sep 28]. In: Adam MP, Ardinger HH, Pagon RA, Wallace SE, Bean LJH, et al, editors. *GeneReviews*® [Internet]. Seattle (WA): University of Washington, Seattle; 1993–2021.
  49. Synofzik M, Sruļijes K, Godau J, Berg D, Schöls L. Characterizing POLG ataxia: clinics, electrophysiology and imaging. *Cerebellum.* 2012;11(4):1002–11.
  50. Hammoud N, Jimenez-Shahed J. Chronic neurologic effects of alcohol. *Clin Liver Dis.* 2019;23(1):141–55.
  51. Monforte R, Estruch R, Valls-Solé J, Nicolás J, Villalta J, et al. Autonomic and peripheral neuropathies in patients with chronic alcoholism. *Arch Neurol.* 1995;52:45–51.
  52. Haller RG. Experimental acute alcoholic myopathy - a histochemical study. *Muscle Nerve.* 1985;8:195–203.
  53. So YT. Diseases of the nervous system. In: Daroff RB, Jankovic J, Mazziotta JC, Pomeroy SL, editors. *Bradley’s neurology in clinical practice.* London: Elsevier; 2016. p. 1226–36.
  54. Baker KG, Harding AJ, Halliday GM, Kril JJ, Harper CG. Neuronal loss in functional zones of the cerebellum of chronic alcoholics with and without Wernicke’s encephalopathy. *Neuroscience.* 1999;91(2):429–38.
  55. Wolffenbuttel BHR, Wouters HJCM, Heiner-Fokkema MR, van der Klauw MM. The many faces of cobalamin (vitamin B12) deficiency. *Mayo Clin Proc Innov Qual Outcomes.* 2019;3(2):200–14.
  56. Grogan PM, Katz JS. Toxic neuropathies. *Neurol Clin.* 2005;23(2):377–96.
  57. Manto M. Toxic agents causing cerebellar ataxias. In: Subramony SH, Dürr A, editors. *Handbook of clinical neurology.* 1st ed. Elsevier B.V.; 2012;12(103):201–13.
  58. Magge RS, DeAngelis LM. The double-edged sword: neurotoxicity of chemotherapy. *Blood Rev.* 2015;29(2):93–100.
  59. Martinez AR, Nunes MB, Nucci A, França MC Jr. Sensory neuropathy and autoimmune diseases. *Autoimmune Dis.* 2012;2012:873587. <https://doi.org/10.1155/2012/873587>.
  60. Zis P, Sarrigiannis PG, Rao DG, Hoggard N, Sanders DS, et al. Cerebellar ataxia with sensory ganglionopathy; does autoimmunity have a role to play? *Cerebellum Ataxias.* 2017;4:20.
  61. Smitt PS, Grefkens J, De LB, Van Den BM, Van PW, et al. Survival and outcome in 73 anti-Hu positive patients with paraneoplastic encephalomyelitis/sensory neuronopathy. *J Neurol.* 2002;249(6):745–53.
  62. Mearns ES, Taylor A, Thomas Craig KJ, Puglielli S, Leffler DA, et al. Neurological manifestations of neuropathy and ataxia in celiac disease: a systematic review. *Nutrients.* 2019;11(2):380. <https://doi.org/10.3390/nu11020380>.
  63. Hadjivassiliou M, Rao D, Wharton S, Sanders D, Grunewald R, et al. Sensory ganglionopathy due to gluten sensitivity. *Neurology.* 2010;75:1003–8.
  64. Gibbons CH, Freeman R. Autonomic neuropathy and coeliac disease. *J Neurol Neurosurg Psychiatry.* 2005;76(4):579–81.
  65. Rossor AM, Carr AS, Devine H, Chandrashekar H, Pelayo-Negro AL, et al. Peripheral neuropathy in complex inherited diseases: an approach to diagnosis. *J Neurol Neurosurg Psychiatry.* 2017;88(10):846–63.
  66. Laurá M, Pipis M, Rossor AM, Reilly MM. Charcot-Marie-Tooth disease and related disorders: an evolving landscape. *Curr Opin Neurol.* 2019;32(5):641–50.
  67. Bogdanova-Mihaylova P, Alexander MD, Murphy RP, Chen H, Healy DG, et al. Clinical spectrum of AIFM1-associated disease in an Irish family, from mild neuropathy to severe cerebellar ataxia with colour blindness. *J Peripher Nerv Syst.* 2019;24(4):348–53.

**Publisher’s Note** Springer Nature remains neutral with regard to jurisdictional claims in published maps and institutional affiliations.